

A NEW MONOSPECIFIC OVINE FAB FRAGMENT ANTIVENOM FOR TREATMENT OF ENVENOMING BY THE SRI LANKAN RUSSELL'S VIPER (*DABOIA RUSSELLII RUSSELLII*): A PRELIMINARY DOSE-FINDING AND PHARMACOKINETIC STUDY

C. A. ARIARATNAM, W. P. MEYER, G. PERERA, M. EDDLESTON, S. A. M. KULERATNE, W. ATTAPATTU, R. SHERIFF, A. M. RICHARDS, R. D. G. THEAKSTON, AND D. A. WARRELL

Faculty of Medicine, University of Colombo, Colombo, Sri Lanka; Therapeutic Antibodies, Inc., Medical College of St. Bartholomew's Hospital, London, United Kingdom; Centre for Tropical Medicine, University of Oxford, Oxford, United Kingdom; Anuradhapura General Hospital, Anuradhapura, Sri Lanka; World Health Organization Collaborating Centre for the Control of Antivenoms and Venom Research Unit, Liverpool School of Tropical Medicine, Liverpool, United Kingdom

Abstract. Russell's viper is the most important cause of life-threatening snake bite and acute renal failure in Sri Lanka. Only equine polyspecific antivenoms imported from India are available. They have not proved effective clinically or in clearing venom antigenemia and they frequently cause reactions. In an attempt to reduce mortality and morbidity, a new monospecific ovine Fab fragment antivenom (PolongaTab[®]; Therapeutic Antibodies, Inc., London, United Kingdom) was raised against Sri Lankan Russell's viper venom. In a preliminary dose-finding study in 35 patients, an initial dose of 3–4 g restored blood coagulability permanently and stopped systemic bleeding, even in severely envenomed patients. Venom antigenemia disappeared within 1 hr of antivenom treatment but recurred, probably as a result of continued absorption of venom from the site of the bite, after the rapid clearance of therapeutic antibody. Twelve patients (34%) experienced early reactions that were usually mild and always responded to epinephrine.

In Sri Lanka, Russell's viper (*Daboia russelii russelii*, Sinhala thith polonga) is responsible for most cases of severe and fatal envenoming.¹ It contributes to an overall incidence of bites exceeding 400 per 100,000 population per year and to a total snake bite mortality of more than 5 per 100,000 population. These are some of the highest figures anywhere in the world. In a study in Anuradhapura, 73% of all bites and all the fatal cases were caused by Russell's vipers.² Russell's viper bite is also one of the commonest causes of renal failure in Sri Lanka, and is responsible for 49% of cases of acute renal failure in Colombo (Ramachandran S and others, unpublished data).

There are striking geographic differences in the composition and clinical effects of Russell's viper venom even within the range of the eastern subspecies *D. r. siamensis*.^{3–8} In Sri Lanka, the clinical features of envenoming by the western subspecies (*D. r. russelii*) are different from those described in other countries, suggesting peculiarities in the composition of the venom. Neurotoxic signs such as ptosis, rhabdomyolysis causing myoglobinuria, and intravascular hemolysis causing hemoglobinuria are important features of systemic envenoming as well as the more familiar coagulopathy, bleeding and renal failure.^{2,9} Local effects of envenoming are usually relatively mild, but swelling, blistering, bruising, necrosis, and secondary infection may develop. Anterior pituitary infarction and a generalized increase in capillary permeability are characteristic of envenoming by *D. r. siamensis* in Burma,³ but these effects have not been observed in Sri Lanka. Antivenom is not manufactured in Sri Lanka but is imported from India (Haffkine Institute, Mumbai and the Serum Institute of India, Pune). These equine polyspecific F(ab')₂ antivenoms are raised against the venom of Indian Russell's vipers (*D. r. russelii*), cobras (*Naja naja*), kraits (*Bungarus caeruleus*), and saw-scaled vipers (*Echis carinatus*). Sri Lanka Russell's viper differs from that of Indian specimens of the same subspecies (*D. r. rus-*

selii), used in the manufacture of these antivenoms in possessing a phospholipase A₂ neurotoxin.^{8,10} In a clinical study of Russell's viper bites in Anuradhapura in 1985, Haffkine antivenom proved clinically disappointing, was not efficient in clearing venom antigenemia, and frequently caused anaphylactic reactions that proved fatal in one case.²

Recently, a new antivenom, PolongaTab[®], has been prepared by Therapeutic Antibodies, Inc. (London, United Kingdom). Unlike conventional antivenoms, which consist mainly of F(ab')₂ fragments obtained by pepsin digestion of concentrated IgG, this new antivenom consists of monomer Fab fragments obtained by papain digestion of sheep IgG.¹¹ The Fab fragments have the theoretical advantages over F(ab')₂ fragments of being more rapidly distributed in the tissues, having a larger apparent volume of distribution, and carrying less risk of early antivenom reactions, which are thought to be the result of complement activation by residual Fc and cross-linked aggregates. These fragments possess only one binding site and so cannot form immune complexes. The first example of an Fab therapeutic antibody was Digibind[®] (Glaxo Wellcome, Uxbridge, United Kingdom), which has been used effectively and safely in many patients with digoxin toxicity.¹² OvineFab antitoxins have been used to treat systemic envenoming by the European adder (*Vipera berus*),^{13,14} North American crotalids,¹⁵ Nigerian saw-scaled or carpet viper (*Echis ocellatus*),¹⁶ and to treat colchicine poisoning.¹⁷ Raising antivenoms in sheep rather than horses has a number of advantages. Many patients may have been sensitized to equine proteins by previous exposure (e.g., anti-tetanus serum) and some may have naturally occurring antibodies to these proteins. Sheep are relatively inexpensive, widely available in developing countries that are unhealthy for horses, and rapidly achieve high circulating levels of high-affinity IgG antibodies. A preliminary dose-finding study of PolongaTab was carried out in preparation for randomized comparison with Indian polyspecific antivenom.

PATIENTS AND METHODS

The study was carried out at Anuradhapura General Hospital in the North Central province of Sri Lanka, about 128 miles north of Colombo, where some 1,000 snake bite cases are admitted each year. Adults with evidence of Russell's viper bite provided written informed consent for investigation and treatment using an information/consent form in Sinhala or Tamil, the two local languages. In the case of minors (children > 5 years old), their parents or legal guardians provided consent. The study protocol was approved by the Ethics Committee of the Faculty of Medicine, University of Colombo. Pregnant women, debilitated patients, and those with other chronic or complicating medical conditions were excluded. Russell's viper bite was proved by identification of the dead snake (in 6 patients), by the clinical observation of incoagulable blood (in 34 patients), or when a description of Russell's viper was associated with symptoms and signs consistent with systemic envenoming by this species such as incoagulable blood, spontaneous systemic bleeding, intravascular hemolysis, (pink plasma, anemia, hemoglobinuria), neurotoxicity (ptosis, external ophthalmoplegia), or rhabdomyolysis (stiff and tender muscles with associated myoglobinuria) (35 patients).

Incoagulable blood was detected using the 20-min whole blood clotting test (20WBCT).¹⁸⁻²⁰ Two milliliters of venous blood was placed in a new, clean, dry glass test tube and left undisturbed for 20 min at room temperature. The tube was then tipped to see if the blood was completely liquid (non-clotting) or whether it contained any clot (clotted). In all cases the diagnosis was later confirmed by detection of Russell's viper venom antigen in serum or urine by enzyme immunoassay (EIA).¹⁶ Epidemiologic data, clinical symptoms and signs, and laboratory results were recorded on a detailed standard case record form, on admission, at least daily thereafter until discharge and on at least one occasion two weeks after antivenom treatment. Local swelling was graded from grade 1 (limited to the bitten segment of the limb only) to grade 5 (covering the whole limb) and was measured daily. Times between bite and admission to the hospital and between bite and the start of the antivenom treatment were recorded.

Antivenom production and assessment. Sheep were immunized with pooled venom from specimens of *D. r. russelii* collected from Sri Lanka and maintained in Liverpool, United Kingdom, Bangkok, Thailand, and Basel, Switzerland. The immunoglobulin fraction of hyperimmune serum was enzymatically cleaved with papain to yield Fab fragments. Each vial was filled with 250 mg of total Fab and freeze-dried. Preclinical testing of the antivenom included neutralization of phospholipase A₂ activity using cresol red as substrate,²¹ and indirect hemolytic activity using human erythrocytes and phosphatidylcholine as substrate.²² The mouse hemi-diaphragm preparation²³ was used to determine the neurotoxic and myotoxic activities of Russell's viper venom and neutralization by antivenom. Lethal venom toxicity (intravenous median lethal dose [LD₅₀]) and antivenom protection (median effective dose [ED₅₀]) against five times the LD₅₀ were determined in mice.²⁴ The antivenom contained less than 0.6% (w/w) papain, as measured by a radioimmunoassay.

Administration of antivenom. All patients were pretreated with epinephrine (0.5 mg of a 0.1% solution given intramuscularly), chlorpheniramine maleate (10 mg given intravenously), and hydrocortisone (100 mg given intravenously) according to the standard practice in this hospital. Freeze-dried antivenom was reconstituted with 10 ml of sterile water for injection, mixed with normal saline (total volume = 300 ml), and infused over a 1-hr period. The patients were closely monitored throughout antivenom administration and for at least 1 hr afterwards to detect any anaphylactic reactions. When these occurred the infusion was stopped immediately and additional epinephrine, antihistamine, and hydrocortisone were administered. The antivenom infusion was completed once symptoms had subsided.

Groups of patients were given initial doses of 2, 3, or 4 g of antivenom and single patients were treated with 1 and 6 g. The 20WBCT was repeated every 6 hr until blood clotting was restored. The test was repeated 6 hr later and then daily until discharge from the hospital. The initial dose of antivenom was repeated if the blood remained incoagulable, or became incoagulable again after initial restoration of coagulability, or if spontaneous systemic bleeding from sites such as gums, nose, gastrointestinal tract, urine, and skin persisted. Patients were kept in the hospital until signs of systemic envenoming resolved and there was improvement in the signs of local envenoming. They were discharged only after their blood had remained coagulable for at least 48 hr. Ancillary treatments included oral paracetamol for pain, benzyl penicillin or flucloxacillin for secondary infections, and peritoneal dialysis for acute renal failure. Tetanus was prevented by giving a booster dose of tetanus toxoid to all patients. Bitten limbs were nursed in the most comfortable position.

Assessment of efficacy. The efficacy of antivenom was assessed by the speed of restoration of blood coagulability using the 20WBCT, by evaluating the other signs of local and systemic envenoming and their resolution, and by following the extinction of venom antigenemia by EIA. Venous blood was taken on admission for the 20WBCT, venom and antivenom kinetic studies, and hematocrit. Additional venous blood samples were taken every 6 hr until blood coagulability was permanently restored. These samples were assayed for venom antigen and therapeutic antibodies by EIA in Liverpool. Free, specific, unbound antivenom was measured using an anti-sheep IgG conjugate for PolongaTab and an anti-horse conjugate for Haffkine antivenom.^{2,16} Pooled sera from 89 individuals of similar ethnic and socioeconomic backgrounds from the Anuradhapura region who had never been bitten by snakes were used to determine background absorbance. The elimination half-life ($t_{1/2}$) of the antivenom was determined by least square regression analysis.^{16,25} Urine was tested daily for protein, blood, hemoglobin, and myoglobin using multiple reagent strips.

RESULTS

Results of preclinical testing are summarized in Table 1. As judged by the murine ED₅₀ test, the monospecific antivenom (PolongaTab) was at least 11 times more effective than the polyspecific (Haffkine) antivenom dose for dose.

During a 5-month period (June–October 1995), 35 pa-

TABLE 1

Comparison of *in vitro* and *in vivo* neutralization of PolongaTab and Haffkine antivenoms

	Indirect hemolysis* 50% neutralization	PLA ₂ activity† % neutralization	Neurotoxicity % neutralization	Myotoxicity % neutralization	Murine ED ₅₀ ‡ (mg/mouse)
PolongaTab	61	100	63§	71§	1.5
Haffkine	620	16	8¶	16¶	>16

* Antivenom concentration (mg/L) required for 50% neutralization using 1.6 mg/L of venom.

† Phospholipase A₂ (PLA₂) neutralization assessed using 3.3 g/L of either antivenom and 10 mg/L of venom.

‡ Assessed using 0.1 mg of venom/mouse (Haffkine showed no protection at the highest possible dose of 16 mg). ED₅₀ = median effective dose.

§ Using 500 mg/L of PolongaTab and 25 mg/L of venom.

¶ Using 2,000 mg/L of Haffkine and 25 mg/L of venom.

tients with proven Russell's viper bites were enrolled into the study. There were 23 males and 12 females from 12 to 48 years of age (mean age = 27). Twenty were farmers who had been bitten while working in the paddy fields or while walking to and from their farms along narrow footpaths. All the bites occurred out of doors, between 6:00 AM and midnight. Thirty-three bites were on the lower limbs, especially the feet and ankles. Seven patients applied tourniquets (usually cloth), that were left in place for 15 min to 3 hr. Five were removed by the medical staff about 1 hr after the patient had been admitted to the hospital. None attended ayurvedic physicians (those practicing traditional Asian Indian treatment with indigenous herbs, drugs, and other techniques) before coming to the hospital. Eighteen patients were admitted directly to Anuradhapura Hospital and the remaining 17 went to the nearest hospital or dispensary where they were assessed before being transferred to Anuradhapura. Twenty-three patients were admitted to the hospital within 3 hr of the bite. The median interval between bite and antivenom administration was 6.5 hr. Six snakes were brought to hospital with the patients they had bitten. All were Russell's vipers. They varied in length from 128 to 156 cm (mean = 140) and four were males.

Clinical features. All patients enrolled in the study had incoagulable blood on admission as determined by the 20WBCT, except for one who had progressing neurologic manifestations and microscopic hematuria (Case A026). All patients had pain at the bite site. Local swelling occurred in 63% and lymphadenopathy in 91%. No patients developed local tissue necrosis. Local swelling, which was maximal 2–3 days after the bite, varied from grade 1 to 5 and regressed over a period of 3–43 days (mean = 11). Eighty-nine percent

of the patients had vomited, 20% had bleeding gums and hematemesis, and 69% had hematuria. Eighty percent of the patients had ptosis and 69% had external ophthalmoplegia, which lasted an average of 2.8 days.

Efficacy of the antivenom. None of the patients died. In all cases, bleeding from the gums, skin, and venipuncture sites and hematuria ceased within 1 hr of starting antivenom treatment. Recurrence of incoagulable blood after its reversal by antivenom treatment was often presaged by hematuria. Details of the patients who needed additional doses to restore blood coagulability permanently are given in Table 2. Seventeen consecutive patients were given an initial dose of 2 g of PolongaTab; in 11 coagulability was restored permanently within 3 hr of starting the infusion. In the remaining six patients blood coagulation was restored only temporarily and they required additional doses of antivenom (up to a total of 4 g). In four, coagulability was restored permanently and in the other two an additional dose (up to a total of 6 g) was required for the permanent restoration of blood coagulation. The next 14 consecutive patients were given an initial dose of 3 g of PolongaTab. Spontaneous bleeding stopped and blood coagulability was permanently restored in 11, but three required an additional dose of 2 g (up to a total of 5 g) for the permanent restoration of coagulability. The last two patients in the study were given an initial dose of 4 g. In one, bleeding stopped immediately and blood coagulability was restored after 6 hr, but the other required an additional dose of 4 g (up to a total of 8 g) to restore blood coagulability permanently.

Elimination of venom antigenemia. All initial doses of antivenom (1, 2, 3, and 4 g) resulted in a rapid decrease to undetectable levels in venom antigenemia within 1 hr of treatment. However, in most cases, antigenemia recurred, usually within the next few hours. One patient was treated with only 1g of Fab because he was atopic and thought to have a high risk of reacting. His blood remained coagulable without systemic bleeding despite his developing progressive neurotoxicity. Venom antigenemia became undetectable 1 hr after antivenom, but recurred after the third day without coagulopathy. No antivenom was detectable in the blood when venom antigenemia recurred, indicating that the Fab fragment had been cleared.

Of the 17 patients given an initial dose of 2 g of PolongaTab, 11 were cured by an initial dose of 2 g of PolongaTab (Figure 1), judging by the reversal signs of systemic envenoming, including coagulopathy. Venom antigen-

TABLE 2
Efficacy of PolongaTab in 33 patients

	Initial and repeated dose			Overall
	2 g	3 g	4 g	
No. treated	17	14	2	33
No. of doses required to restore coagulation permanently	25	17	3	4
1 dose	11	11	1	23
2 doses	4	3	1	8
3 doses	2	0	0	2
Haffkine antivenom given before admission	9	7	1	17
No. in which one dose cleared venom	6	5	1	12
Time (hr) taken for complete venom clearance from serum (mean ± SEM)	71.6 ± 10.8 n = 17	66.3 ± 14.7 n = 12	10.0 ± 6.1 n = 2	64.5 ± 8.5 n = 31

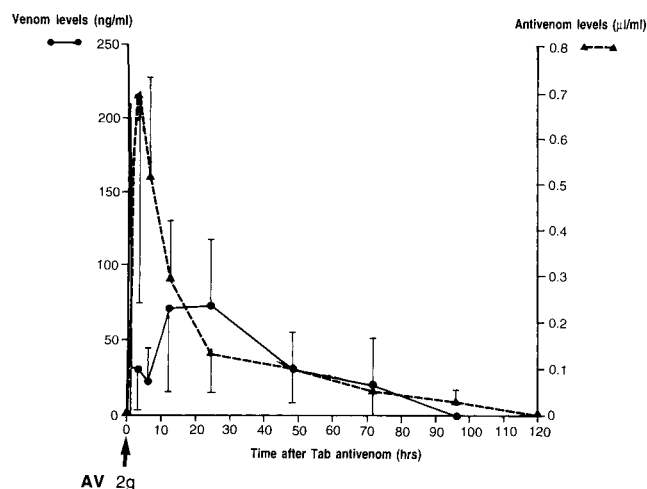


FIGURE 1. Levels of venom antigen (unbroken line) and antivenom (broken line) in 11 patients treated with a single dose of 2 g Fab antivenom (AV) where indicated (arrow). Bars represent ± 2 SEM.

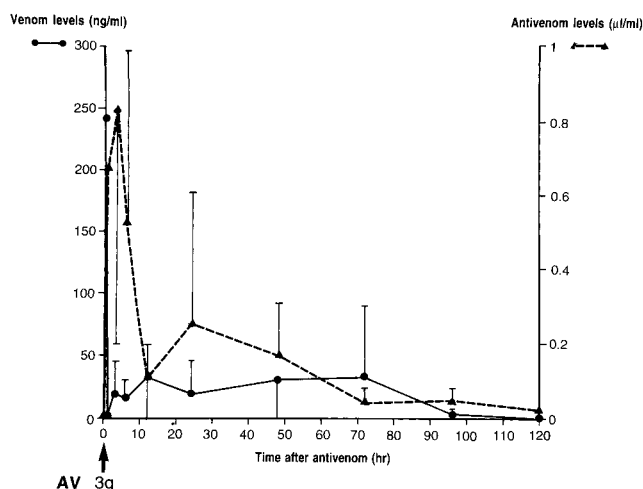


FIGURE 2. Levels of venom antigen (unbroken line) and antivenom (broken line) in 11 patients treated with a single dose of 3 g of Fab antivenom (AV) where indicated (arrow). Bars represent ± 2 SEM.

emia recurred 6–12 hr after treatment in all cases and finally disappeared within a mean ± 2 SEM of 72 ± 22 hr ($n = 17$) (Table 2). Fourteen patients with admission venom levels similar to those treated with 2 g of antivenom were treated with an initial dose of 3 g of antivenom (Figure 2). They showed the same rapid initial clearance of venom antigenemia (within 1 hr of treatment) but this recurred after about 1 hr. After 24–48 hr, antivenom levels had decreased to very low levels. In one of the two patients treated with 4 g of antivenom, venom antigenemia cleared completely and permanently within 1 hr of treatment.

In the two groups of 11 patients each treated with 2 g and 3 g of antivenom, mean ± 2 SEM elimination half times were 28.1 ± 18.7 hr and 25.6 ± 13.5 hr, respectively. In the two patients treated with one dose each of 1 g and 4 g of PolongaTab, the elimination half times of the antivenom were 16.3 and 17.2 hr, respectively.

Pretreatment with Haffkine antivenom. In the groups of patients treated initially with 2 and 3g of PolongaTab, 9 and 7 respectively had been treated with Haffkine antivenom before enrollment into the study. Their initial venom antigen levels were lower than in those who had not been pretreated but the clinical outcome was similar.

Antivenom reactions. Despite routine prophylaxis with epinephrine, H_1 -anti-histamine, and corticosteroid, 12 (34%) of the 35 patients developed early anaphylactic reactions to PolongaTab (Table 3) as demonstrated by vomiting (2), pru-

ritus (11), urticaria (11), headache (2), hypotension (2), cough (2), rhonchi (1), wheezing (1), and rigors (2). Two patients developed late, serum sickness-type reactions (pruritus, urticaria, fever, and arthralgia) 6 and 10 days after treatment with antivenom.

Illustrative case histories. *Case history 1.* A 12-year-old Sinhalese girl (A001) (weight = 26.5 kg, height = 128 cm), was bitten at 9:30 PM on the medial aspect of her right foot while walking home along a country track near Abyawawa. The snake, described as polonga, was not killed. A tourniquet was applied immediately and released when she was admitted to Anuradhapura Hospital only 15 min after the bite. She appeared moribund. She had pain, bleeding and swelling at the site of bite, and an episode of dizziness. She was confused and shocked, complaining of abdominal pain and vomiting. Her right foot was tender and swollen up to the ankle with bleeding fang marks 25 mm apart. The right inguinal lymph nodes were enlarged and tender. Her blood pressure was initially 110/70 mm of Hg but became unrecordable over the next 30 min, the pulse rate was regular at 130 beats/min, and her temperature was 37.2°C . There was gingival hemorrhage, blood in the vomitus, and she was also passing fresh bright red blood rectally. She had ptosis, external ophthalmoplegia, and reduced movements of both lower limbs. Full neurologic assessment was not possible due to severe pain and swelling of the bitten limb but the lower limbs appeared weak.

TABLE 3
Early anaphylactic reactions in 35 patients*

	Dose					Total
	1 g	2 g	3 g	4 g	6 g	
No. treated	1	17	14	2	1	35
% of patients developing early reactions	100 (1)	29 (5)	36 (5)	0	100 (1)	34 (12)
Occurrences on which antivenom was given	1	25	17	2	2	47
Total no. of reactions	1	5	7	0	2	15
% reactions/antivenom dose	100	20	41	0	100	32

* Values in parentheses are the number of patients in each dose group who experienced reactions.

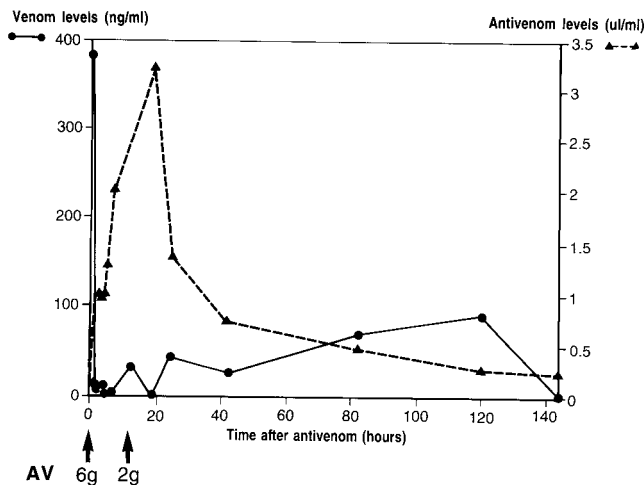


FIGURE 3. Serum venom antigen concentration (ng/ml) and serum therapeutic antivenom (AV) concentrations ($\mu\text{l/ml}$) in a 12-year-old patient (A001) admitted with severe envenoming. She was treated with 6 g of PolongaTab (at time 0, 2 hr after the bite) and 12 hr later, a second dose of 2 g was given (indicated by the **arrows**).

Her blood was incoagulable as assessed by the 20WBCT. The patient was given epinephrine (0.25 mg intramuscularly), hydrocortisone (50 mg intravenously), and chlorpheniramine (5 mg intravenously) as prophylaxis in view of the large dose of antivenom judged to be necessary. Six grams of PolongaTab was infused in 300 ml of normal saline over a period of 5 hr and 40 min. The patient developed severe anaphylactic reactions, with urticaria, vomiting, coughing, and hypotension, during the infusion of antivenom. These were managed by stopping the infusion temporarily and giving additional doses of epinephrine (0.2 mg subcutaneously), chlorpheniramine (5 mg intravenously), and gelofusin infusion (600 ml). Within 25 min of starting antivenom treatment, all bleeding had ceased and her blood pressure had been restored. Within 3 hr, her blood had become coagulable and antivenom antigenemia had cleared (Figure 3). However, 12 hr later her blood was again found to be incoagulable, associated with an increase in venom antigenemia (Figure 3), and she passed about 300 ml of reddish-black urine. Another 2 g of PolongaTab was given over a 3-hr period, and was followed by episodes of vomiting, coughing, and occipital headache, but with a decrease in venom antigenemia (Figure 3) that finally disappeared six days after the bite. Following this infusion her blood remained coagulable. She had marked leukocytosis ($26,200/\text{mm}^3$ with 93% neutrophils). Blood urea and electrolyte levels were normal. She had a good urine output following alkaline diuresis. Local swelling increased up to her mid thigh on the third day after the bite.

By the fifth day after the bite, ptosis and external ophthalmoplegia had resolved completely. However, she developed bilateral lower limb weakness, sustained clonus, flexor plantars, and bilateral brisk reflexes but had no abnormality of sensation or proprioception. She was transferred to Colombo General Hospital for a full neurologic assessment and radiologic investigation including a computed tomography (CT) scan. By this time she had an asymmetrical flaccid paraparesis without sensory or sphincter involvement and

with bilateral ankle clonus. Signs were more on the left side than on the right, with a positive Beever's sign, indicating a spinal lesion at the level of T10. The results of all the investigations, including the CT scan to exclude a parasagittal or spinal cord lesion, myelography, an electroencephalogram, and nerve conduction studies, were negative. A clinical diagnosis of hemorrhage or infarction of the anterior spinal cord and bleeding due to severe systemic envenoming was made. She was started on regular physiotherapy and gradually regained her muscle power. Six months after the bite, she had grade 4 (Medical Research Council) muscle power, was walking without support, and attending school regularly. After 46 months, there was further improvement but she was still walking unsteadily and could not run.

Case history 2. A 20-year-old trader (A026) was bitten on his left hand by a 156-cm long female Russell's viper. He was admitted to Anuradhapura General Hospital 1 hr after the bite when he had only local swelling and pain at the bite site with tender left axillary lymphadenopathy. His blood clotted normally on admission. His blood remained coagulable but he developed progressive bilateral partial ptosis, diplopia, and external ophthalmoplegia. The urine was positive for blood. He had a history of bronchial asthma and was on regular medication. An initial dose of 1g of PolongaTab was given 8 hr after the bite. He developed mild urticaria on his trunk and neck but responded well to treatment. Three hours after antivenom treatment, which rapidly decreased the venom antigenemia, a marked clinical improvement was observed in the neurologic deficits. The neurotoxic signs completely resolved within 1 day. Local swelling extended up to his left axilla after three days and then completely regressed over the next 17 days. He developed serum sickness (pruritus, urticaria, fever, and arthralgia) 10 days after antivenom and responded to a course of prednisolone. At follow-up two weeks after the bite he was well.

DISCUSSION

We report for the first time production of an antibody specific for Sri Lankan Russell's viper venom and a clinical trial of this new antivenom in human victims of Russell's viper bite in Sri Lanka. Many clinicians prefer to use a polyspecific antivenom because this removes the necessity of identifying the species of snake responsible for the bite. However, monospecific antivenoms should contain more specific neutralizing activity per unit of equine/ovine protein so that a smaller dose of antivenom is needed to cure the envenoming and the incidence of both potentially life-threatening early anaphylactic and late serum sickness reactions should be decreased.

An encouraging aspect of our results was the rapid neutralization by the new antivenom of venom procoagulants and hemorrhagic components of Sri Lankan *D. r. russelii* venom, as shown by restoration of blood coagulability and cessation of systemic bleeding, even in one very severely envenomed patient (see Case history 1). We have established that an initial dose of 3–4 g of this particular batch of PolongaTab antivenom is needed to ensure permanent restoration of blood coagulability in the majority of patients. An initial dose of 2 g of PolongaTab was not enough to produce permanent restoration of blood coagulability and

elimination of venom antigenemia in the majority of patients. With this dose, recurrence of bleeding, blood incoagulability, and venom antigenemia indicated that levels of antivenom were inadequate to neutralize the circulating venom, probably because of redistribution of venom into the circulation and/or the entry of more venom into the systemic circulation from a depot at the bite site. The pharmacokinetic data suggested rapid clearance of the Fab antivenom from the circulation. In bite victims of the Malayan pit viper (*Calloselasma rhodostoma*) treated with conventional F(ab')₂ monospecific antivenom, recurrence of incoagulability, and other clinical effects coincided with recurrence of unbound venom levels.²⁶ Similar effects have been observed with a monospecific ovine Fab antivenom used in the treatment of *Echis ocellatus* bite in Nigeria,¹⁶ and with a crotalid polyspecific ovine Fab antivenom for treating crotalid envenoming in the United States.²⁷

The pharmacokinetic studies demonstrate the rapid renal clearance of Fab antivenom, a potential disadvantage of this IgG fragment. This batch of Fab antibody was eliminated faster than the Fab antivenom developed for treatment of *Echis ocellatus* envenoming ($t_{1/2} = 16\text{--}28$ hr compared with 4.3 hr).¹⁶ A single initial dose of Fab antivenom does not produce circulating levels of antivenom that persist for long enough to cover continuing absorption of venom from its site of inoculation. Using a rabbit model to compare Fab and F(ab')₂ antivenoms, it was shown that F(ab')₂ bound to *Vipera aspis* venom was eliminated more rapidly than Fab-venom complexes.²⁸

The neurotoxic effect of Sri Lankan Russell's viper venom, which is not observed clinically after bites by the eastern subspecies (*D. russelii siamensis*),^{3,5} is attributed to the action of a presynaptically-acting phospholipase A₂.^{2,8,10} In most of our patients, antivenom was not effective in reversing this presynaptic neuromuscular blockade, but in Case 2 (see above) there was remarkable improvement within 3 hr of this treatment. The batch of PolongaTab used in this study was a prototype antivenom that had a relatively high ED₅₀ in mice and a high content of Fc fragments. Potency has now been improved and residual Fc fragments largely eliminated by ion-exchange chromatography in the hope of reducing the incidence of early anaphylactic reactions seen in the present study.

Acknowledgments: We thank Dr. S. Ward (Department of Pharmacology and Therapeutics, University of Liverpool) for help with pharmacokinetic analysis and E. Berry for preparing the manuscript. *In vitro* assessments of PolongaTab were completed by R. G. A. Jones (Therapeutic Antibodies Inc.).

Financial support: This study was supported by the Association of Physicians "Links with Developing Countries" and Therapeutic Antibodies, Inc. No author has an undisclosed conflict of interest.

Authors' addresses: C. A. Ariaratnam and R. Sheriff, Department of Clinical Medicine, Faculty of Medicine, University of Colombo, PO Box 271, No. 25 Kynsey Road, Colombo 8, Sri Lanka. W. P. Meyer, Therapeutic Antibodies, Inc., Medical College of St. Bartholomew's Hospital, Charterhouse Square, London EC1M 6BQ, United Kingdom. G. Perera, and M. Eddleston, and D. A. Warrell, Centre for Tropical Medicine, John Radcliffe Hospital, Headington, Oxford OX3 9DU, United Kingdom. A. M. Kularatne and W. Attapattu, Anuradhapura General Hospital, Anuradhapura, Sri Lanka. A. M. Richards and R. D. G. Theakston, World Health Organization, Collaborating Centre for the Control of Antivenoms and Venom Re-

search Unit, Liverpool School of Tropical Medicine, Pembroke Place, Liverpool L3 5QA, United Kingdom.

Reprint requests: D. A. Warrell, Centre for Tropical Medicine, John Radcliffe Hospital, Headington, Oxford OX3 9DU, United Kingdom.

REFERENCES

- de Silva A, Ranasinghe L, 1983. Epidemiology of snake bite in Sri Lanka: a review. *Ceylon Med J* 28: 144–154.
- Phillips RE, Theakston RDG, Warrell DA, Galigedara Y, Abeysekera DTDG, Dissaanayaka P, Hutton RA, Aloysius DJ, 1988. Paralysis, rhabdomyolysis and haemolysis caused by bites of Russell's viper (*Vipera russelli pulchella*) in Sri Lanka: failure of Indian (Haffkine) antivenom. *Q J Med* 257: 691–716.
- Myint-Lwin, Phillips RE, Tun-Pe, Warrell DA, Tin-Nu-Swe, Lay MM, 1985. Bites by Russell's viper (*Vipera russelli siamensis*) in Burma: haemostatic, vascular and renal disturbances and responses to treatment. *Lancet* 2: 1259–1264.
- Than-Than, Hutton RA, Myint-Lwin, Khin-Ei-Han, Soe-Soe, Tin-Nu-Swe, Phillips RE, Warrell DA, 1988. Haemostatic disturbances in patients bitten by Russell's viper (*Vipera russelli siamensis*) in Burma. *Br J Haematol* 69: 513–520.
- Warrell DA, 1989. Snake venoms in science and clinical medicine. 1. Russell's viper; biology, venom and treatment of bites. *Trans R Soc Trop Med Hyg* 83: 732–740.
- Woodhams BJ, Wilson SE, Xin BC, Hutton RA, 1990. Differences between the venoms of two subspecies of Russell's viper (*Vipera russelli pulchella* and *Vipera russelli siamensis*). *Toxicon* 28: 427–433.
- Wüster W, Otsuka S, Malhotra A, Thorpe RS, 1992. Population systematics of Russell's viper: a multivariate study. *Biol J Linn Soc* 47: 97–113.
- Tsai IH, Lu PJ, Su JC, 1996. Two types of Russell's viper revealed by variation in phospholipases A₂ from venom of the subspecies. *Toxicon* 34: 99–109.
- Jeyarajah R, 1984. Russell's viper bite in Sri Lanka. A study of 22 cases. *Am J Trop Med Hyg* 33: 506–510.
- Jayanthi GP, Gowda TV, 1988. Geographical variation in India in the composition and lethal potency of Russell's viper (*Vipera russelli*) venom. *Toxicon* 26: 257–264.
- Theakston RDG, Smith DC, 1995. Therapeutic antibodies to snake venoms. Landon J, Chard T, eds. *Therapeutic Antibodies*. Chapter 6. London: Springer-Verlag, 109–133.
- Hickey AR, Wegner TL, Carpenter VP, Tilson HH, Hlatky MA, Furberg CD, 1991. Digoxin immune Fab therapy in the management of digitalis intoxication: safety and efficacy results of an observational surveillance study. *J Am Coll Cardiol* 17: 690–698.
- Karslon-Stüber C, Persson H, Heath A, Smith D, Al-Abdulla IH, Sjöström L, 1997. First clinical experiences with specific sheep Fab fragments in snake bite. Report of a multicentre study of *Vipera berus* envenoming. *J Intern Med* 241: 53–58.
- Smith DC, Reddi KR, Laing G, Theakston RDG, Landon J, 1992. An affinity purified ovine antivenom for the treatment of *Vipera berus* envenoming. *Toxicon* 30: 865–871.
- Consore P, Egen NB, Russell FE, Gerrish K, Smith DC, Sidki A, Landon JT, 1995. Comparison of a new ovine antigen binding fragment (Fab) antivenin for United States crotalidae with the commercial antivenin for protection against venom induced lethality in mice. *Am J Trop Med Hyg* 53: 507–510.
- Meyer WP, Habib AG, Onayade AA, Yakubu A, Smith DC, Nasidi A, Daudu IJ, Warrell DA, Theakston RDG, 1997. First clinical experience with a new ovine Fab *Echis ocellatus* snake bite antivenom in Nigeria: randomized comparative trial with Institute Pasteur serum (Ipser) African antivenom. *Am J Trop Med Hyg* 56: 291–300.
- Sabouraud AE, Urtizberea M, Cano NJ, Grandeorge M, Rouzioux JM, Scherrmann G, 1992. Colchicine-specific Fab fragments after colchicine disposition in rabbits. *J Pharmacol Exp Ther* 260: 1214–1219.
- Warrell DA, Davidson NMCD, Greenwood BM, Ormerod LD,

- Pope HM, Watkins BJ, Prentice CRM, 1977. Poisoning by bites of the saw-scaled or carpet viper (*Echis carinatus*) in Nigeria. *Q J Med* 46: 33–62.
19. Warrell DA, Looareesuwan S, Theakston RDG, Phillips RE, Chanthavanich P, Viravan C, Supanaranond W, Karbwang J, Ho M, Hutton RA, Vejecho S, 1986. Randomized comparative trial of three monospecific antivenoms for bites by three Malayan pit vipers (*Calloselasma rhodostoma*) in southern Thailand: clinical and laboratory correlations. *Am J Trop Med Hyg* 35: 1235–1247.
 20. Sano-Martins IS, Fan HW, Castro SCB, Tomy SC, França FOS, Jorge MT, Kamiguti AS, Warrell DA, Theakston RDG, BIASG, 1994. Reliability of the simple whole blood clotting test (WBCT20) as an indicator of low plasma fibrinogen concentration in patients envenomed by *Bothrops* snakes. *Toxicon* 32: 1045–1050.
 21. Canzaini G, Seki C, Vidal JC, 1982. Accessibility of the active site of crotoxin B in the crotoxin complex. *Toxicon* 20: 809–822.
 22. Al-Abdulla IH, Sidki AM, Landon J, 1991. An indirect haemolytic assay for assessing antivenoms. *Toxicon* 29: 1043–1046.
 23. Bülbiring E, 1946. Observation on the isolated phrenic nerve diaphragm preparation of the rat. *Br J Pharmacol* 1: 38–61.
 24. Theakston RDG, Reid HA, 1983. Development of simple standard assay procedures for the characterization of snake venoms. *Bull World Health Organ* 61: 949–956.
 25. Theakston RDG, Fan HW, Warrell DA, Dias de Silva W, Higashi HG, and the Butantan Institute Antivenom Study Group (BIASG), 1992. Use of enzyme immunoassays to compare the efficacy and assess dosage regimens of three Brazilian *Bothrops* antivenoms. *Am J Trop Med Hyg* 47: 593–604.
 26. Ho M, Warrell MJ, Warrell DA, Bidwell D, Voller A, 1986. A critical reappraisal of the use of enzyme-linked immunosorbent assays in the study of snake bite. *Toxicon* 24: 211–221.
 27. Dart RC, Selfert SA, Carroll L, Hall E, Bayer-Hassan LV, Curry SC, Kitchens CS, Garcia RA, 1997. Affinity-purified mixed monospecific crotalid antivenom ovine Fab for the treatment of crotalid venom poisoning. *Ann Emerg Med* 30: 33–39.
 28. Rivière G, Schumet V, Audebert F, Sabouraud A, Debray M, Scherrmann JM, Bon C, 1997. Effect of antivenom on venom pharmacokinetics in experimentally envenomed rabbits: towards an optimization of antivenom therapy. *J Pharmacol Exp Ther* 281: 1–8.