

See discussions, stats, and author profiles for this publication at: <https://www.researchgate.net/publication/6586346>

# Zeil Nelson and Wade–Fite stains to demonstrate medlar bodies of chromoblastomycosis

Article in *Journal of Cutaneous Pathology* · February 2007

DOI: 10.1111/j.1600-0560.2006.00572.x · Source: PubMed

---

CITATIONS

9

---

READS

216

4 authors, including:



**Menaka Dilani Samarawickrema Lokuhetty**  
University of Colombo

63 PUBLICATIONS 626 CITATIONS

[SEE PROFILE](#)



**Mannikawadumesthri Vipula Chandu de Silva**  
Faculty of Medicine, university of Colombo

112 PUBLICATIONS 1,007 CITATIONS

[SEE PROFILE](#)

Some of the authors of this publication are also working on these related projects:



Synovial sarcoma [View project](#)



Prostate carcinoma [View project](#)

## Letter to the Editor

# Zeil Neelson and Wade-Fite stains to demonstrate medlar bodies of chromoblastomycosis

To the Editor,

The characteristic fungal bodies of chromoblastomycosis, known as Medlar bodies, are visualized as golden brown rounded bodies in routine hematoxylin and eosin (H&E) stained tissue sections of the skin (Fig. 1). We report a hitherto undocumented staining pattern of Medlar bodies that will be useful when they are not identified in routine H&E stains, in cases with a high index of clinical suspicion.

Chromoblastomycosis is a chronic fungal infection of skin and subcutaneous tissue seen in rural populations of tropical and subtropical regions. The commonly reported causative fungi are *Fonsecaea pedrosoi*, *Phialophora verrucosa* and *Cladosporium carrionii*.<sup>1</sup> The organisms after gaining entry to the body through traumatic skin injury produce a slow growing verrucous nodule or a plaque.<sup>2</sup> The histological diagnosis of the disease is by staining tissue sections of skin with the H&E stain to demonstrate Medlar bodies.<sup>3,4</sup>

A 72-year-old female presented with a non-itchy warty growth on the dorsum of the left foot of one-year duration. The warty growth had a hyperkeratotic center with peripheral scarring. The clinical differential diagnosis in this patient included warty

tuberculosis and chromoblastomycosis. H&E-stained sections of the lesion showed epidermal hyperplasia and a dense chronic inflammatory infiltrate with ill-formed granulomata within the dermis. Although these histological features supported a diagnosis of chromoblastomycosis, the characteristic Medlar bodies were not seen. Therefore, the Zeil Neelson stain (ZNS) was performed to rule out the possibility of warty tuberculosis. In the ZNS sections, Medlar bodies were seen prominently as dark grayish oval bodies against a light blue background (Fig. 2). Subsequently, ZNS was performed on tissue sections of three confirmed cases of chromoblastomycosis retrieved from the departmental case files. A similar pattern of staining was seen in all three cases confirming that Medlar bodies of chromoblastomycosis are stained by the ZNS, traditionally used to demonstrate acid fast bacilli. Following this, Wade-Fite staining (WFS) was done on tissue sections in the above patients. Medlar bodies stained positively with WFS in a pattern similar to that seen with the ZNS (Fig. 3).

Medlar bodies were easier to identify in the ZNS and WFS than in the routine H&E-stained slides as all inflammatory cells and the background stained

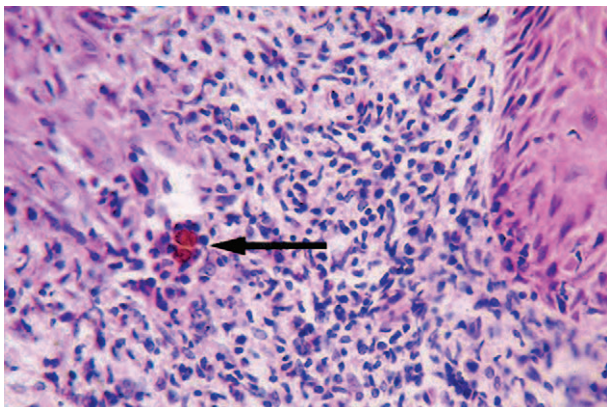


Fig. 1.

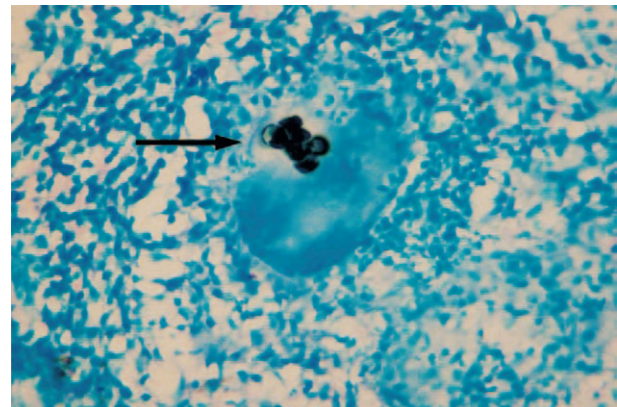


Fig. 2.

## Letter to the Editor

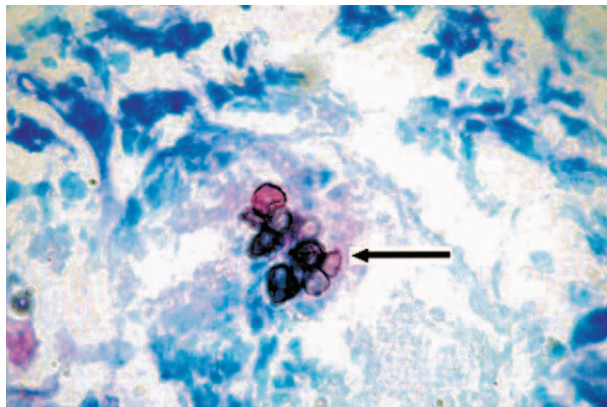


Fig. 3.

in a uniform light blue color, enhancing the detection of dark grayish blue Medlar bodies (Figs 2, 3).

When compared with the traditional special stains used to demonstrate Medlar bodies (such as PAS and silver methenamine), ZNS and WFS are easier stains to perform than the silver methenamine stain but requires a longer duration of time than the PAS stain. The reason, the Medlar bodies were seen in the ZNS and not in the H&E stain in the initial patient, could have been due to the inflammatory infiltrate making it difficult to detect the Medlar bodies. There is a possibility that Medlar bodies could have made their appearance in the deeper sections done for ZNS, although adequate number of deeper sections had already been examined.

We conclude that the ZNS and WAS are useful stains in suspected chromoblastomycosis when Medlar bodies are not seen in routine H&E-stained sections.

### Acknowledgements

We thank S. Y. Shriani, technical officer in our department, for performing these stains.

*MDS Lokuhetty  
VS Alahakoon  
BDMU Kularatne  
MVC De Silva*

Department of Pathology, Faculty of Medicine,  
University of Colombo, Colombo, Sri Lanka  
email: alaha@visualnet.lk

### References

1. Sharma NL, Sharma RC, Grover PS, et al. Chromoblastomycosis in India. *Int J Dermatol* 1999; 38: 846.
2. Rubin HA, Bruce S, Rosen T, et al. Evidence of percutaneous inoculation as the mode of transmission for chromoblastomycosis. *J Am Acad Dermatol* 1991; 25: 951.
3. Bonifaz A, Carrasco-Gerard E, Saul A. Chromoblastomycosis: clinical and mycologic experience of 51 cases. *Mycoses* 2001; 44: 1.
4. McGinnis MR. Chromoblastomycosis and phaeohyphomycosis: new concepts, diagnosis and mycology. *J Am Acad Dermatol* 1983; 8: 1