



ELSEVIER



Research

Location and Diameter of Intracranial Meningioma as Predictors of Peritumoral Brain Oedema and Mass Effect

Udari Apsara Liyanage, MBBS, MD (Radiology), FRCR(Lond)^a, Yasith Mathangasinghe, MBBS^{a*}, Pradeep Kumara Wijerathne, MBBS^b, Sahathevan Vithoosan, MBBS^c and Aruna Pallewatte, MBBS, MD (Rad), FCPS (Rad), FANMB (Nuc Med), FRCR (Lond)^d

^a Department of Anatomy, Faculty of Medicine, University of Colombo, Sri Lanka

^b General Surgery Section, National Hospital of Sri Lanka, Colombo, Sri Lanka

^c General Medicine Section, National Hospital of Sri Lanka, Colombo, Sri Lanka

^d Neuroradiology and MRI Section, National Hospital of Sri Lanka, Colombo, Sri Lanka

ABSTRACT

Introduction: The presence of peritumoral oedema or mass effect with intracranial meningiomas is associated with poor clinical outcomes. This study aimed to investigate magnetic resonance (MR) morphologic features of meningioma, which can predict peritumoral oedema and mass effect.

Methods: Data of 100 consecutive patients diagnosed with meningioma on MRI brain at the neurosurgical MRI unit, National Hospital of Sri Lanka, reported by a Consultant Radiologist were analysed in a retrospective study. Binary logistic regression models were fitted to identify predictors of perilesional oedema and mass effect.

Results: Female-to-male ratio was 5.8:1. Patients were aged 18–80 years. Majority (n = 78) were in supratentorial compartment with 16 at parasagittal location. Cerebellopontine angle was the commonest infratentorial site (n = 9). Size of meningiomas ranged from 1.1 to 9.1 cm (largest dimension). Mass effect (n = 68), perilesional oedema (n = 37), and midline deviation (n = 31) were the most commonly reported complications. Maximum diameter of meningioma and its location significantly predicted the presence of perilesional oedema [$\chi^2(2,47) = 6.03, P = .049$, Nagelkerke $R^2 = 18.2\%$] and mass effect [$\chi^2(2,71) = 16.73, P = .000$, Nagelkerke $R^2 = 39.4\%$] in two logistic regression models.

Conclusion: The probability of mass effect and perilesional oedema increased with the maximum diameter. Meningioma extending to

both supratentorial and infratentorial compartments had the highest risk of having concomitant perilesional oedema and mass effect.

RÉSUMÉ

Introduction : La présence d'œdème péritumoral ou d'effet de masse dans les cas de méningiomes intracâniens est associée à de mauvais résultats cliniques. Cette étude vise à examiner les caractéristiques morphologiques de résonance magnétique (RM) des méningiomes qui pourraient permettre de prédire l'œdème péritumoral ou l'effet de masse.

Méthodologie : Cent dossiers consécutifs de patients ayant reçu un diagnostic de méningiome après un examen d'IRM du cerveau à l'unité d'IRM neurochirurgicale de l'Hôpital national du Sri Lanka ont été rapportés par un radiologiste consultant. Des modèles de régression logistique binaire ont été appliqués afin d'identifier les prédicteurs d'œdème périlésionnel et d'effet de masse.

Résultats : Le ratio femme/hommes était de 5,8:1. L'âge des patients variait entre 18 et 80 ans. La majorité (n = 78) des atteintes se situaient dans la région sus-tentorielle, dont 16 en position parasagittale. L'angle pont-cérébelleux était le site sous-tentorielle le plus commun (n = 9). La taille des méningiomes variait entre 1,1 et 9,1 cm (plus grande dimension). L'effet de masse (n = 68), l'œdème périlésionnel (n = 37) et le déplacement de la ligne médiane du

Funding: This research received no specific grants from any funding agency in the public, commercial, or not-for-profit sector.

Conflicts of Interests: The authors declare that there are no conflicts of interests.

Contributors: All authors contributed to the conception or design of the work, the acquisition, analysis, or interpretation of the data. All authors were involved in drafting and commenting on the article and have approved the final version.

Ethical Approval: The study was approved by the Ethics Review Committee, Faculty of Medicine, University of Colombo (reference No. EC/14/014; approved on 5 March 2014).

Data Sharing Statement: The data are available from the corresponding author on reasonable request.

* Corresponding author: Yasith Mathangasinghe, MBBS, Faculty of Medicine, Department of Anatomy, University of Colombo, 25, Kynsey Road, Colombo, Sri Lanka, 00800.

E-mail address: yasith@anat.cmb.ac.lk (Y. Mathangasinghe).

cerveau (n = 31) étaient les complications les plus communément signalées. Le diamètre maximal du méningiome et son emplacement permettaient de prédire de manière significative la présence d'œdème périlésionnel [χ^2 (2,47) = 6,03, $P = 0,049$, Nagelkerke $R^2 = 18,2$ %] et d'effet de masse [χ^2 (2,71) = 16,73, $P = ,000$, Nagelkerke $R^2 = 39,4$ %] dans les deux modèles de régression logistique.

Keywords: Neuroimaging; magnetic resonance imaging; brain neoplasms; complications

Introduction

Meningioma is a tumour originating from the leptomeningeal layers of the brain and spinal cord accounting for approximately 30% of all primary intracranial tumours [1]. While being the commonest extra axial tumour encountered in the neurosurgical practice, the reported incidence of meningiomas is rising steadily [1]. The current modality of choice for diagnostic imaging of meningioma is magnetic resonance imaging (MRI) [2].

Even though the majority of meningiomas are benign [3], they can be associated with significant morbidity and mortality [4,5], caused by the effects of the tumour, as well as by the adverse effects of treatment [6]. The presence of peritumoral oedema (Figure 1A) and mass effect (Figure 1B) in patients with meningioma is reported to have higher odds of developing complications and poor clinical outcomes [7,8]. Moreover, a higher ratio of oedema to tumour volume is also a significant predictor of mortality [8]. Therefore, it is essential to have a mechanism of prognostication on MR diagnosis of meningioma, which will give directive for regular monitoring as well as for deciding on surgical intervention.

Findings of the previous studies looking for associations between poor prognostic factors such as perilesional oedema, and MRI morphology of tumour such as tumour size, location are controversial. Gawlitza et al found no associations between peritumoral oedema indices and the tumour size [9], whereas Lobato [10] and Simis [11] found that the larger tumours are associated with a higher risk of associated perilesional oedema on the MRI. Simis also described that tentorial meningiomas have less peritumoral oedema. In contrast, Lobato et al found only a moderate increase in risk of oedema with tentorial lesions, whereas tumours located in the frontal convexity and the middle third of the falx had highest odds of peritumoral oedema [10]. Nonetheless, another study based on computerized tomograms failed to show any association between the location and the size of oedema [12].

In this context, we aimed to explore MR morphologic features of meningioma which could predict two known poor prognostic factors; peritumoral oedema and mass effect.

Methods

The study protocol was approved by the Ethics Review Committee, Faculty of Medicine, University of Colombo,

Conclusion : La probabilité d'effet de masse et d'œdème périlésionnel augmente avec le diamètre maximum. Les méningiomes qui s'étendent dans les deux compartiments sus- et sous-tentorial présentent le risque le plus élevé d'œdème périlésionnel et d'effet de masse concomitants.

Sri Lanka (Reference number: EC/14/014; approved on 5 March 2014). This study retrospectively analysed MRI findings and relevant clinical data of 100 consecutive patients who were diagnosed on MRI brain to have meningioma. Data were retrieved from the unit database at the neurosurgical MRI unit of the National Hospital of Sri Lanka. The sample size was calculated for binary logistic regression analysis with five covariates according to the formula by Peduzzi et al [13], where proportion of positive cases of peritumoral oedema and mass effect were considered as 0.672 [11] and 0.667 [8], respectively. Since the resulting numbers were less than 100, a sample size of 100 was used as suggested by Long [14].

All MR images were reported by the senior consultant radiologist in charge of the unit experienced in neuroimaging. Imaging protocol of the unit included T1 weighted, T2 weighted, and FLAIR sequences in axial, sagittal, and coronal planes of brain and post contrast (intravenous 0.1 mL/kg Dimethylglumine Gadopentatate [Magnevist], Bayer, Germany) T1W images acquired in axial, sagittal, and coronal plane of the brain using 1 Tesla Siemens Harmony, MRI Scanner.

Measurements for tumour size were performed in axial, coronal, and sagittal T2/FLAIR images obtained with 5 mm gaps. Longest diameters of the tumour in anteroposterior, craniocaudal, and transverse directions were measured on the workstation during reporting. The maximum dimension out of above was recorded for the study. Oedema was assessed visually by analyzing perilesional signal changes as described in Figure 1A. Mass effect assessed by the degree of pressure effects and distortion of surrounding anatomical structures (Figure 1B).

The data were analysed using R (version 3.5.0), RStudio (version 1.1.447) and GraphPad Prism (version 8.0.2). Binary logistic regression models were fitted to identify predictors of perilesional oedema (model 1) and mass effect (model 2). Size, location (tentorial compartment and the side) of meningioma, age, and sex of the patients were considered as the independent variables. All the statistical analyses were conducted at a priori alpha of 0.05.

Results

Of 100 patients, female to male ratio was 5.8:1. Patients were aged 18 to 80 years. The median age was 50 years (IQR = 42–64 years). Ninety-one patients had single meningiomas, while nine had multiple meningiomas. Patients with

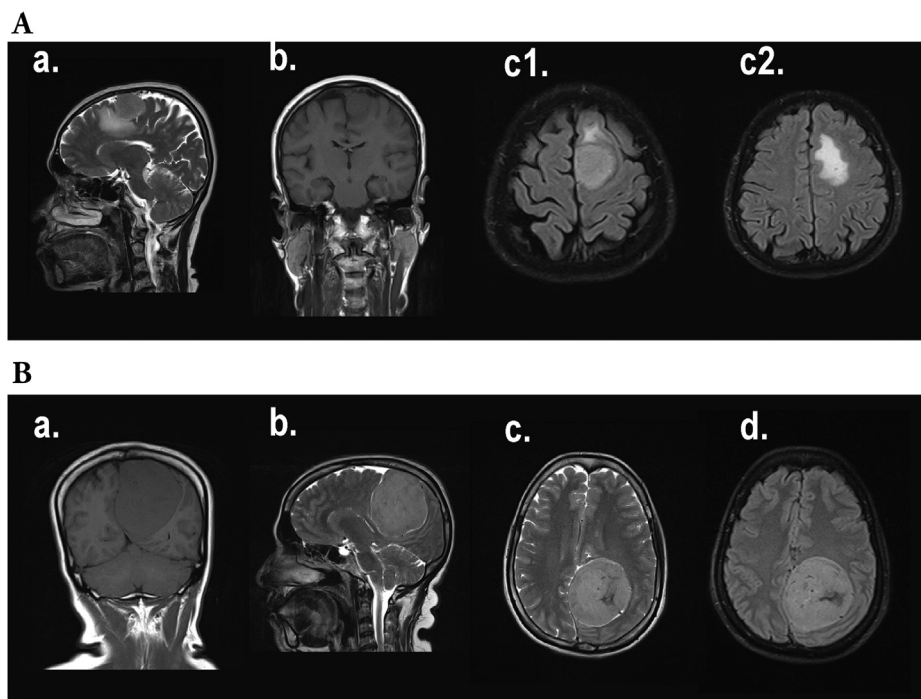


Figure 1. Magnetic resonance images (MR) of meningioma | (A) a. T2W sagittal, b. T1W coronal, c1, c2 FLAIR axial MR images of the brain showing perilesional oedema. In a and c—as T2 and FLAIR hyperintensity surrounding the tumour. b—T1 hypointensity immediately around the tumour; mainly in white matter making finger-like projections in to the white matter of the brain, features are better demonstrated in T2 and FLAIR images than in T1 images. (B) a. T1W coronal, b. T2W sagittal, c. T2W axial, and d. FLAIR axial MR images of the brain showing mass effect. Images demonstrate compression of the adjacent anatomical structures due to pressure effects from the tumour. Falx cerebri is curved and deviated to right side (contralateral side) by the left side tumour. Sulci/gyri on left occipital region posterior to the tumour are also compressed. The posterior aspect of the corpus callosum is depressed by the mass.

missing data were excluded case-wise in the statistical analyses if at least a single predictor or outcome variable were not reported (size [n = 11], side [n = 1], age [n = 4], sex [n = 12]).

Size and Location of Meningioma

The majority (n = 78) of meningiomas were located exclusively in the supratentorial compartment, while 15 were in the infratentorial compartment. Five meningiomas were extending to both the compartments. In two cases, multiple meningiomas were seen in both supratentorial and infratentorial compartments. Parasagittal was the commonest supratentorial location (n = 16) followed by frontal (n = 10) and frontoparietal (n = 10) locations. Cerebellopontine angle was the commonest infratentorial site (n = 9). Among the single meningiomas (n = 91), 43 were right sided, 40 were left sided, and 8 were centrally located. The median of the maximum diameter of the meningioma was 3.9 cm (IQR = 2.9–4.1 cm). The maximum diameter of the smallest and the largest meningioma detected in our sample were 1.1 cm and 9.1 cm, respectively.

Complications Detected on Magnetic Resonance Imaging

Commonly reported complications of meningiomas were mass effect on adjacent brain (n = 68), perilesional oedema (n = 37), and midline deviation (n = 31). Three patients

had meningioma causing venous sinus thrombosis. Hydrocephalus was present in 14 patients, and cerebellopontine angle was the commonest location of meningioma in cases complicated with hydrocephalus (n = 4, 29%).

Predictors of Perilesional Oedema (Model 1)

Continuous independent variables were distributed normally, and the preliminary multicollinearity diagnostic tests were negative for the binary logistic regression analysis. The first model examining the predictors of perilesional oedema contained two independent variables: maximum diameter of the meningioma and its location, that is, supratentorial, infratentorial, single tumour extending to both compartments or multiple meningiomas involving both compartments. The full model containing both predictors was statistically significant [$\chi^2(2, 47) = 6.03, P = .049$]. The model explained between 12.0% (Cox and Snell R^2) and 18.2% (Nagelkerke R^2) of the variance. The strongest predictor of perilesional oedema was the maximum diameter of the meningioma, recording an odds ratio of 1.46 (95% CI = 0.95–2.39). This indicated that for every additional increase of centimetre of the maximum diameter was associated with 1.5 times increased risk of developing perilesional oedema. The odds ratio of the location of the meningioma was 0.36 (95% CI = 0.07–1.25), of those with single meningioma extending to both supratentorial and infratentorial compartments had the highest risk of

having perilesional oedema. The box and whiskers plot in Figure 2A (left) and percentage component bar chart in Figure 2B (top) show the associations of maximum diameter and tentorial location with peritumoral oedema, respectively.

Predictors of Mass Effect (Model 2)

The second model examining the predictors of mass effects also contained the same independent variables: maximum diameter of the meningioma and its location (as described above). The full model containing both the predictors was statistically significant [$\chi^2(2, 71) = 16.73, P = .000$]. The model explained between 21.0% (Cox and Snell R^2) and 39.4% (Nagelkerke R^2) of the variance. The strongest predictor of mass effect was the maximum diameter of the meningioma, recording an odds ratio of 3.34 (95% CI = 1.70–

9.04). This indicated that for every additional increase of centimetre of the maximum diameter was associated with over three times increased risk of developing mass effects. The odds ratio of the location of the meningioma was 1.46 (95% CI = 0.43–7.77), of those with multiple meningiomas in both supratentorial and infratentorial compartments had the highest risk of having mass effects. The box and whiskers plot in Figure 2A (right) and percentage component bar chart in Figure 2B (bottom) show the associations of maximum diameter and tentorial location with mass effect, respectively.

Discussion

The relatively benign nature of meningioma has led to conservative management specially for the majority of the incidentally detected lesions. Therefore, MRI is used in

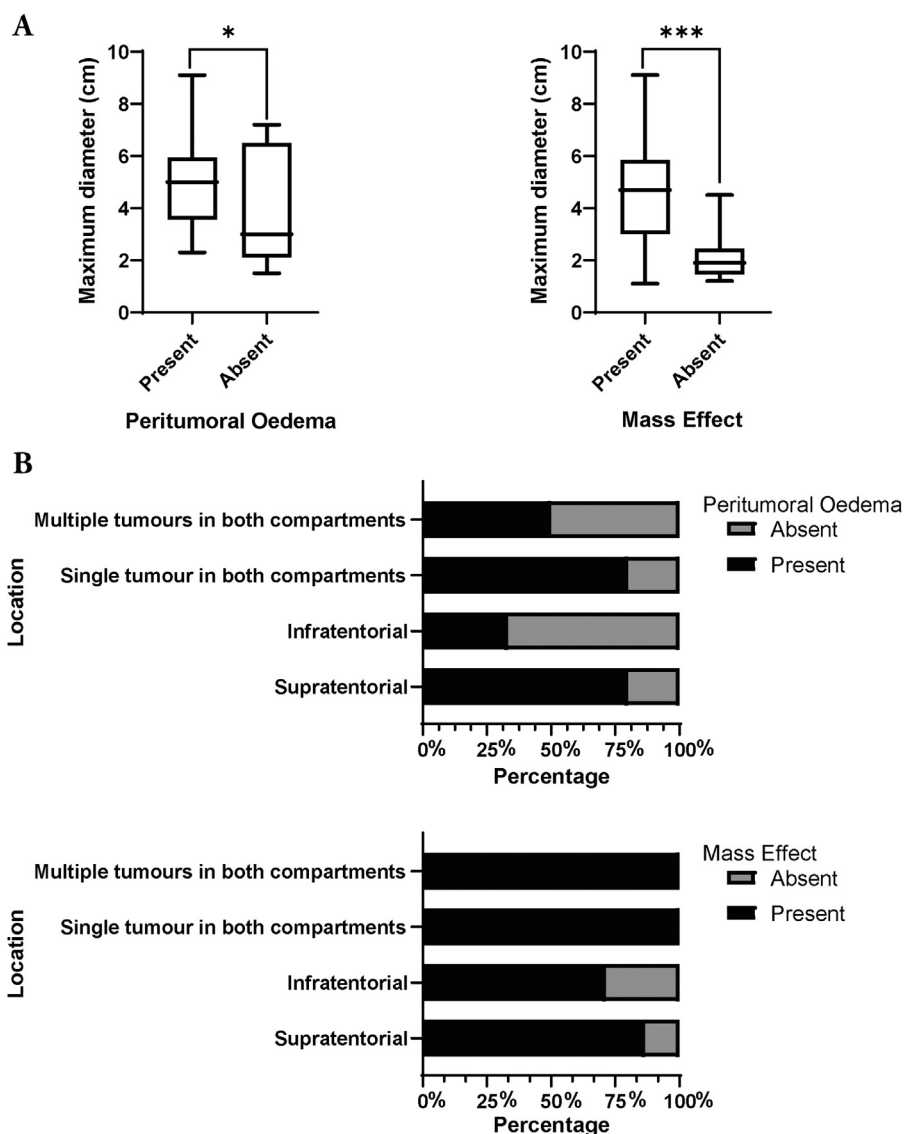


Figure 2. Predictors of peritumoral oedema and mass effect | (A) The box and whiskers plots show that the tumours with larger diameters are associated with peritumoral oedema (left) and mass effect (right). (B) The percentage component bar charts demonstrate the associations of the tentorial location with peritumoral oedema (left) and mass effect (right). The level of significance is indicated as $P < .05$ (*), $P < .001$ (***)

such cases as the only tool to diagnose meningioma and for the early detection of complications during follow-up. The findings of this study suggest that the maximum diameter and the location of the meningioma to be the most effective predictors of peritumoral oedema and mass effect, compared with the side of the tumour located in the cranium, age, and sex of the patient.

Peritumoral brain oedema is detected by MRI among approximately two-thirds of the patients with meningioma [11,15]. Pathophysiology of peritumour oedema is not clearly understood; however, it may be affected by the expression of aquaporin 4 channels [9], matrix metalloproteinase-9 (MMP-9) (REF [16]), and vasculoendothelial growth factor (VEGF) (REF [16]) in tumour tissue in addition to mechanical compression [17]. Studies have shown that the presence of peritumour oedema is associated with increased intracranial pressure [10] seizures [18,19] and poor surgical outcomes [11,20].

Here, we suggest the maximum diameter of the meningioma as a predictor of peritumour oedema and mass effect, which can be easily and accurately measured without the need of sophisticated computational software. Therefore, the proposed technique can be effectively incorporated into clinical practice as an indirect index of prognosis. This study also highlights the importance of the location in predicting oedema and mass effects. Lesions extending to both supratentorial and infratentorial regions need to be closely monitored due to the increased risk of development of peritumour oedema and mass effects. Moreover, since the extent of oedema can be predicted by the maximum diameter of the tumour, small lesions with unusually extensive oedema might suggest an alternative pathology.

Limitations of the Study

Since this was a retrospective study, the temporal associations of developing peritumoral oedema and mass effects could not be computed. Moreover, unavailability of histology to confirm the diagnosis of meningioma was a limitation of this study. Nevertheless, since only a minority of cases with meningioma are managed surgically, this limitation could not have been overcome. Exclusion of cases with missing data in the logistic regression analyses may have underestimated or overestimated the individual contributions of the predictors to the overall models. The images were reported by a single radiologist which might limit the internal validity. However, the reporting radiologist is with over 15 years of experience as a postgraduate trainer and has work experience as the reporting radiologist in charge of the neurosurgical MRI unit. Furthermore, the usage of a clear criteria to obtain the measurements should minimize this limitation.

Conclusion

Based on our findings, the maximum diameter of meningioma and its location could predict both perilesional oedema and mass effect. Every additional increase of centimetre of the

maximum diameter was associated with 1.5 times increased risk of developing perilesional oedema and over three times increased risk of developing mass effects. Meningioma extending to both supratentorial and infratentorial compartments had the highest risk of having concomitant perilesional oedema and mass effects. These findings could be considered when planning therapeutic strategies for meningiomas.

Acknowledgements

The authors wish to thank the staff of the Neurosurgical MRI unit.

Supplementary Data

Supplementary data to this article can be found online at <https://doi.org/10.1016/j.jmir.2020.04.004>.

References

- [1] Perry, A. (2018). Meningiomas. In: *Practical surgical neuropathology: a diagnostic approach* (pp. 259–298). Philadelphia, PA: Elsevier.
- [2] Goldbrunner, R., Minniti, G., & Preusser, M., et al. (2016). EANO guidelines for the diagnosis and treatment of meningiomas. *Lancet Oncol* 17, e383–e391.
- [3] Moliterno, J., Cope, W. P., & Vartanian, E. D., et al. (2015). Survival in patients treated for anaplastic meningioma. *J Neurosurg* 123, 23–30.
- [4] Meskal, I., Gehring, K., Rutten, G.-J. M., & Sitskoorn, M. M. (2016). Cognitive functioning in meningioma patients: a systematic review. *J Neurooncol* 128, 195–205.
- [5] Islim, A. I., Mohan, M., & Moon, R. D., et al. (2019). Incidental intracranial meningiomas: a systematic review and meta-analysis of prognostic factors and outcomes. *J Neurooncol* 142, 211–221.
- [6] Bartek, J. Jr., Sjövik, K., & Förander, P., et al. (2015). Predictors of severe complications in intracranial meningioma surgery: a population-based multicenter study. *World Neurosurg* 83, 673–678.
- [7] Trivedi, M. M., Raghavan, A., Das, P., Recinos, P. F., & Kshetry, V. R. (2019). Peritumoral edema and surgical outcome in secretory meningiomas: a matched cohort analysis. *J Neurol Surg B Skull Base* 80, A043.
- [8] Djindjian, M., Caron, J., Athayde, A., & Fevrier, M. (1988). Intracranial meningiomas in the elderly (over 70 years old). *Acta Neurochir (Wien)* 90, 121–123.
- [9] Gawlitza, M., Fiedler, E., Schob, S., Hoffmann, K.-T., & Surov, A. (2017). Peritumoral brain edema in meningiomas depends on aquaporin-4 expression and not on tumor grade, tumor volume, cell count, or Ki-67 labeling index. *Mol Imaging Biol* 19, 298–304.
- [10] Lobato, R., Alday, R., & Gomez, P., et al. (1996). Brain oedema in patients with intracranial meningioma. *Acta Neurochir (Wien)* 138, 485–494.
- [11] Simis, A., de Aguiar, P. H. P., Leite, C. C., Santana, P. A. Jr., Rosemberg, S., & Teixeira, M. J. (2008). Peritumoral brain edema in benign meningiomas: correlation with clinical, radiologic, and surgical factors and possible role on recurrence. *Surg Neurol* 70, 471–477.
- [12] Go, G. K., Wilmink, J. T., & Molenaar, W. M. (1988). Peritumoral brain edema associated with meningiomas. *Neurosurgery* 23, 175–179.
- [13] Peduzzi, P., Concato, J., Kemper, E., Holford, T. R., & Feinstein, A. R. (1996). A simulation study of the number of events per variable in logistic regression analysis. *J Clin Epidemiol* 49, 1373–1379.
- [14] Long, J. S. (19). Regression models for categorical and limited dependent variables. In: *Advanced quantitative techniques in the social sciences* Vol 7. California: Sage Publications.
- [15] Drummond, K. J., Zhu, J.-J., & Black, P. M. (2004). Meningiomas: updating basic science, management, and outcome. *Neurologist* 10, 113–130.

- [16] Reszec, J., Hermanowicz, A., Rutkowski, R., Turek, G., Mariak, Z., & Chyczewski, L. (2015). Expression of MMP-9 and VEGF in meningiomas and their correlation with peritumoral brain edema. *Biomed Res Int* 2015, 646853.
- [17] Bradac, G. B., Ferszt, R., Bender, A., & Schorner, W. (1986). Peritumoral edema in meningiomas. A radiological and histological study. *Neuroradiology* 28, 304–312.
- [18] Lieu, A.-S., & Howng, S.-L. (1999). Intracranial meningiomas and epilepsy: incidence, prognosis and influencing factors. *Epilepsy Res* 38, 45–52.
- [19] Englot, D. J., Magill, S. T., Han, S. J., Chang, E. F., Berger, M. S., & McDermott, M. W. (2016). Seizures in supratentorial meningioma: a systematic review and meta-analysis. *J Neurosurg* 124, 1552–1561.
- [20] Flannery, T., & Poots, J. (2019) *Gamma knife radiosurgery for meningioma. Leksell radiosurgery* Vol. 34 (pp. 91–99). Basel: Karger Publishers.