

Blue rubber bleb naevus syndrome

P R Nanayakkara¹ and D N Samarasekera²

(Index words: Multiple haemangiomas, management)

Introduction

Blue rubber bleb naevus syndrome (BRBNS) is a rare clinical entity characterised by multiple haemangiomas commonly occurring in the skin and the gastrointestinal (GI) tract. The association between these cutaneous cavernous haemangiomas and similar lesions in the GI tract was first described in 1860 and the acronym BRBNS was given by Bean in 1958 [1]. Patients may present with massive GI bleeding or anaemia due to chronic occult bleeding.

Case report

The patient we describe is a male, 22 years at present. At birth his parents had noticed a lump on the left posterior chest over the scapula which gradually enlarged, for which medical advice was sought at the age of 3 years. An attempt had been made to excise the lump and the histology of the excised portion had shown an intramuscular haemangioma. At the age of seven, he had reported to the local hospital with melaena and anaemia. Upper GI endoscopy done during his hospital stay had shown multiple upper GI vascular malformations. Coagulation studies and routine blood investigations had been normal.

On admission to our unit at the age of 14, in addition to the GI haemangiomas (figure 1) he had multiple cutaneous vascular lumps, notably on his tongue, back of chest, shaft of penis, right knee joint and leg. The CT scan of brain was normal and the ultrasound abdomen excluded similar lesions in the liver, kidneys and spleen. Slit lamp examination of the fundus was also normal.

Later he presented with repeated episodes of pallor and melaena, which were conservatively managed with haematinics and blood transfusions. Several attempts at controlling the bleeds by injecting a sclerosant into the haemangiomas in the stomach failed to control the bleeds. Radio-isotope scans using Tc99 labelled red cells at each admission did not identify a definite site of GI bleeding. Since the bleeding continued despite conservative measures, an exploratory laparotomy was done at the age of 15 years. At laparotomy, multiple transmural and mucosal haemangiomas were seen in the stomach, small bowel and colon. A right hemicolectomy and local excision of several gastric and small bowel haemangiomas (identified by on-table enteroscopy) were carried out. His symptoms

improved and the bleeding episodes decreased after surgery. Three years later he presented with one episode of melaena and pallor, for which he received a blood transfusion. For the past 4 years he has been asymptomatic.

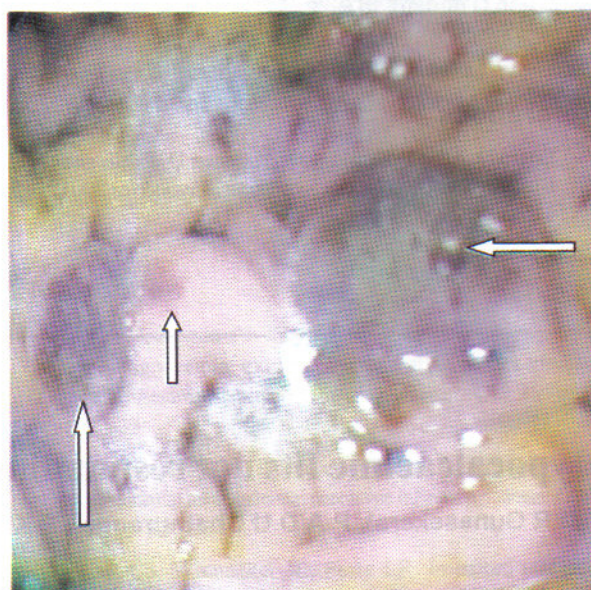


Figure 1. Upper GI endoscopy view of the gastric mucosa showing multiple haemangiomas of varying sizes

Discussion

BRBNS is a rare condition in which patients commonly present with multiple cutaneous and GI haemangiomas. This condition can also affect other viscera such as liver, spleen, kidney, bladder, lungs, parotid, thyroid, central nervous system and eyes [1]. The majority of cases are sporadic, but an autosomal dominant inheritance has been reported [2]. It affects all races and both sexes equally. These lesions increase as the child grows older.

If the clinical features are mild, a conservative approach should be adopted. Cutaneous lesions do not warrant treatment unless they are cosmetically unacceptable. When the GI bleeding is mild, haematinics usually suffice, when severe, may need blood transfusion.

¹Registrar, University Surgical Unit, The National Hospital of Sri Lanka, and ²Professor in Surgery, Faculty of Medicine, University of Colombo, Kynsey Road, Colombo 8.

Correspondence: DNS, e-mail <samarasekera58@yahoo.co.uk>. Conflicts of interest: none declared.

Case reports

Since these malformations are scattered throughout the gastrointestinal tract and new ones may develop later in life, surgical resections should be avoided [1]. When conservative methods fail and the lesions are confined to a particular segment of the gut, surgical resection is recommended.

Stabilisation of the lesions and control of bleeding may be achieved temporarily with certain pharmacological agents [1,3,4] but the lesions recur once the drugs are discontinued. The haemangiomas can also be treated endoscopically either by sclerotherapy or band ligation [5]. Endoscopic laser (YAG) photocoagulation is a newer technique with encouraging results [6]. When there is a familial occurrence, genetic counselling is recommended.

References

1. Ertem D, Acar Y, Kotiloglu E, Yucelten D, Pehlivanoglu E. Blue Rubber Bleb Nevus Syndrome. *Pediatrics* 2001; **107**: 418-20.
 2. McKusick VA. Blue rubber bleb nevus (Bean syndrome). In: McKusick VA, ed. *Mendelian Inheritance in Man*. 11th ed. Baltimore, MD: John Hopkins University Press; 1994: 212-13.
 3. Boente MC, Cordisco MR, Frontini MV, Asial RA. Blue rubber bleb nevus (Bean syndrome): evolution four cases and clinical response to pharmacologic agents. *Paediatric Dermatology* 1999; **16**: 222-7.
 4. Enjolras E. Vascular tumours and vascular malformations: are we at the dawn of a better knowledge? *Paediatric Dermatology* 1999; **16**: 238-41.
 5. Sala FT, Urquijo PJJ, Lopez VB, Pertejo PV, Berenguer LJ. Blue naevus syndrome: endoscopic treatment by sclerosis and banding ligation. *Gastroenterology and Hepatology* 1999; **22**: 136-8.
 6. Morris L, Lynch PM, Gleason WA Jr, Schauder C, Pinkel D, Duvic M. Blue rubber bleb nevus syndrome: laser photocoagulation of colonic hemangiomas in a child with microcytic anemia. *Paediatric Dermatology* 1992; **9**: 91-4.
-