

lined by ciliated columnar, stratified squamous or rarely gastric epithelium. Most contain a clear jelly like fluid. These cysts are extramural and share the common muscular wall of the oesophagus [2]. The oesophageal duplication cysts are commonly asymptomatic. If gastric mucosa persists it may lead to ulceration, haemorrhage and perforation. An enlarging cyst can cause dysphagia, airway obstruction and repeated lung infections. Radiographically these cysts appear as a mediastinal mass. Barium studies show a filling defect indistinguishable from common tumours such as leiomyoma. At endoscopy there is a bulge with overlying normal mucosa. If the duplication cyst communicates with the oesophagus the barium fills in a blind pouch [3].

Complete surgical excision is the treatment of choice [4]. Excision is done via thoracotomy or by video assisted thoracoscopy. Regular follow up of these patients is

essential as impaired propulsive activity of the oesophagus due to damage to oesophageal musculature may result in gastro-oesophageal reflux disease.

References

1. Boyee GA. Oesophagus: anatomy and structural anomalies. In: Yamada T, ed. *Textbook of Gastroenterology*, 3rd ed. Philadelphia: Lippincott William & Wilkins. 1999; 1188.
2. Martin ND. Intra-thoracic oesophageal duplication cyst: a review. *Journal of Gastrointestinal Surgery* 2007; **11**: 773-7.
3. Rafal RB. Imaging of oesophageal cyst. *American Journal of Gastroenterology* 1991; **86**: 1809-11.
4. Acuff TE. Thoracoscopic excision of bronchiogenic cyst. *Annals of Thoracic Surgery* 1993; **55**: 196-200.

Heterotopic pancreas in the body of the stomach

S A Seneviratne¹, I T Ramanayaka¹ and D N Samarasekera¹

A 45-year old man was admitted with a history of epigastric pain for 3 months. Physical examination, routine blood tests and abdominal ultrasound were unremarkable.

Oesophagogastroduodenoscopy (OGD) showed a sessile mass with normal overlying mucosa arising from the upper part of the body on the anterior wall of the stomach close to the lesser curvature (Figure 1). Multiple biopsies were taken and the histology showed normal gastric mucosa. Contrast enhanced CT scan of the abdomen showed a submucosal mass arising from the body of the stomach suggestive of a gastro-intestinal stromal tumour (GIST). There was no evidence of infiltration across the stomach wall or regional lymphadenopathy. Endoscopic ultrasound (EUS) showed a predominantly hyperechoic submucosal lesion (Figure 2). The patient underwent open surgery and the lesion was completely excised. Histology showed heterotopic pancreatic tissue in the submucosa of the stomach.

Pancreatic heterotopia is defined as presence of abnormally situated pancreatic tissue, without any anatomical or vascular continuity with the normal pancreas [1]. This can occur at a variety of sites in the gastrointestinal tract, most frequently in the stomach and the small intestine

[2]. Most patients are asymptomatic, but symptoms develop when it is complicated by inflammation, bleeding, obstruction or malignant transformation [3]. In the gastrointestinal tract, stomach is the commonest site for pancreatic heterotopia (up to 36%) followed by duodenum and jejunum. More than 95% of the gastric lesions are found in the antrum of the stomach, the majority of them situated close to the greater curvature [4]. Pancreatic heterotopia in the body of the stomach is rare. Ectopic pancreatic tissue can undergo complications that can occur in the normal pancreas, including acute and chronic pancreatitis, abscess and pseudocyst formation and malignant transformation.

Barium swallow may show a filling defect in the stomach. The OGD allows direct visualisation and biopsies to be taken. However, most of the biopsies are superficial and non diagnostic. Endoscopic ultrasound and fine needle aspiration allows evaluation of cytology from deep lesions with a sensitivity of 80-100% [5]. Contrast enhanced CT scan findings cannot differentiate ectopic pancreatic tissue from other gastric submucosal lesions such as GIST. In the majority, the diagnosis is made by histological evaluation following resection of a symptomatic or a suspicious lesion.

¹University Surgical Unit, National Hospital of Sri Lanka.

Correspondence: SAS, e-mail <sanjeewa_sa@yahoo.com>. Received 22 July 2008 and accepted 10 January 2009. Competing interests: none declared.

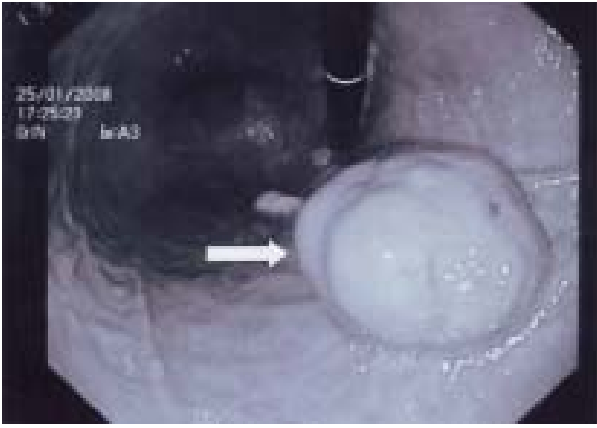

Figure 1. OGD view of the sessile growth (arrow) in the body of the stomach.

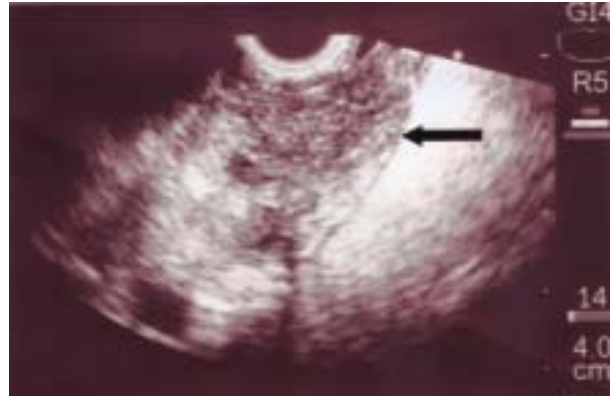


Figure 2. Endoscopic ultrasound image showing the submucosal growth (arrow).

References

1. Guillou L, Nordback P, Gerber C, Schneider RP. Ductal adenocarcinoma arising in a heterotopic pancreas situated in a hiatal hernia. *Archives of Pathology and Laboratory Medicine* 1994; **118**: 568-71.
2. Christodoulidis G, Zacharoulis D, Barbanis S, Katsogridakis E, Hatzitheofilou E. Heterotopic pancreas in the stomach: a case report and literature review. *World Journal of Gastroenterology* 2007; **13**: 6098-100.
3. Cullen JJ, Weydert C, Hinkhouse MM, Ritchie J, Domann FE, Spitz D, Oberley LW. The role of manganese superoxide dismutase in the growth of pancreatic adenocarcinoma. *Cancer Research* 2003; **63**: 1297-303.
4. Chandan VS, Wang W. Pancreatic heterotopia in the gastric antrum. *Archives of Pathology and Laboratory Medicine* 2004; **128**: 111-2.
5. Thoeni RF, Gedgaudas RK. Ectopic pancreas: usual and unusual features. *Gastrointestinal Radiology* 1980; **5**: 37-42.